

# **Uterine and splenic trauma rupture to a pregnant woman: A case report**

**Diomandé Gondo<sup>1</sup>, Védi Loué<sup>1</sup>, Koffi N'guessan<sup>1</sup>, Denis Effoh<sup>1</sup>, Eléonore Gbary<sup>1</sup>, Kacou Yenon<sup>2</sup>, Abdoulaye Ouattara<sup>3</sup>, Klinna Coulibaly<sup>3</sup>, Adélaïde Kouassi<sup>1</sup>**

<sup>1</sup>Department of Gynecology and Obstetrics, Félix Houphouët-Boigny's University of Cocody- Abidjan, Faculty of Medical Sciences, University Hospital of Cocody, Cote d'Ivoire

<sup>2</sup>Department of Digestive and Visceral Surgery, Félix Houphouët-Boigny's University of Cocody- Abidjan, Faculty of Medical Sciences, University Hospital of Cocody, Cote d'Ivoire

<sup>3</sup>Intensive Care Unit, Félix Houphouët-Boigny's University of Cocody- Abidjan, Faculty of Medical Sciences, University Hospital of Cocody, Cote d'Ivoire.

## **Email address:**

[drLouevedi@yahoo.fr](mailto:drLouevedi@yahoo.fr) (V. Loué)

## **To cite this article:**

Diomandé Gondo, Védi Loué, Koffi N'guessan, Denis Effoh, Eléonore Gbary, Kacou Yenon, Abdoulaye Ouattara, Klinna Coulibaly, Adélaïde Kouassi. Uterine and Splenic Trauma Rupture to a Pregnant Woman: A Case Report. *Journal of Gynecology and Obstetrics*. Vol. 2, No. 6, 2014, pp. 95-99. doi: 10.11648/j.jgo.20140206.14

---

**Abstract:** *Background:* In developed countries where statistics are well defined, 6 to 7 % of road accidents complicate pregnancies and involve pregnant women as a pedestrian in about 4 % of cases. *Case:* A 39 years old pregnant woman had been victim of a road accident at six months of pregnancy, when as a pedestrian. She was struck directly on the abdomen by a motorcyclist resulting in multiple traumas. She presented in the aftermath of the accident, a cranial vault fracture without mass effect or commitment, a left bimalleolar non-displaced fracture, uterine rupture with fetal death and splenic rupture. Emergency laparotomy performed revealed intra-abdominal injuries and allowed treatment. A conservative uterine suture and total splenectomy were performed. *Conclusion:* Trauma to a pregnant woman can have serious consequences for both mother and fetus. A careful physical examination and good strategy for requesting additional examinations and a good organization of the medical team rehearsed for this purpose can provide better overall care.

**Keywords:** Uterine and Splenic Rupture-Road Traffic Accident-Pregnancy

---

## **1. Introduction**

Trauma during pregnancy has become relatively common. In developed countries where statistics are well defined, traumas complicate 6 to 7 % of pregnancies [1] and are the commonest non-obstetric cause of fetal death. In severe injuries the fetal death rate is near 60 % and the maternal death close to 10 % [2]. Accidental injuries described in this association are multiple with varied incidences. In descending order, the main causes of these injuries are represented by highway accidents (55%), fall (13%) and physical assault (10%) [2-4]. Accidents involving a pregnant woman as a pedestrian can be particularly serious and concerns about 4% of trauma and pregnancy. We report in this study, the case of a pregnant woman, who had been victim of a road accident, when as a pedestrian she was hit by a motorcyclist.

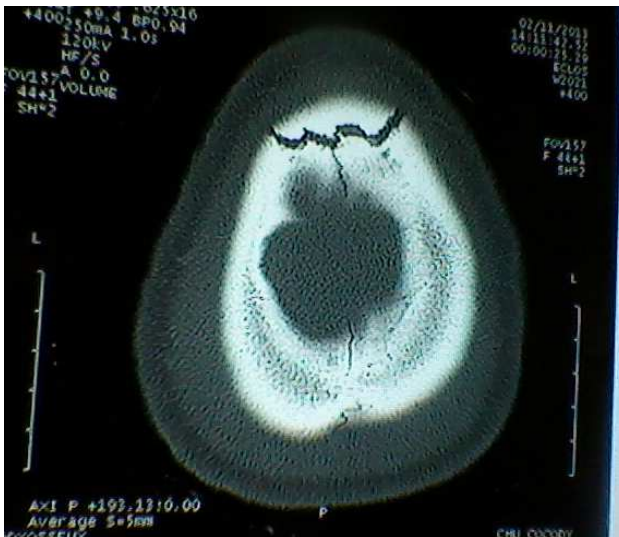## **2. Case Presentation**

The patient, a 39-year-old pregnant fourth-parous woman, was about six months pregnant, when going to the market; she was struck by a motorcyclist in Aboisso (city located about 120 km from Abidjan, the economic capital of Cote d'Ivoire) on November 2, 2013 at about 9h00. She was hit directly on the abdomen by the motor and was projected at about 2 meters from the point of impact. It was followed by an immediate loss of consciousness. After the accident she was transferred to Aboisso's General Hospital where she received first aid of the ABCDE care included: airway, breathing, circulation, disability, and exposure. She was then transferred to Abidjan by the emergency medical assistance for trauma.

She was admitted at the gynecology emergency unit of the University Hospital of Cocody- Abidjan on November 2,

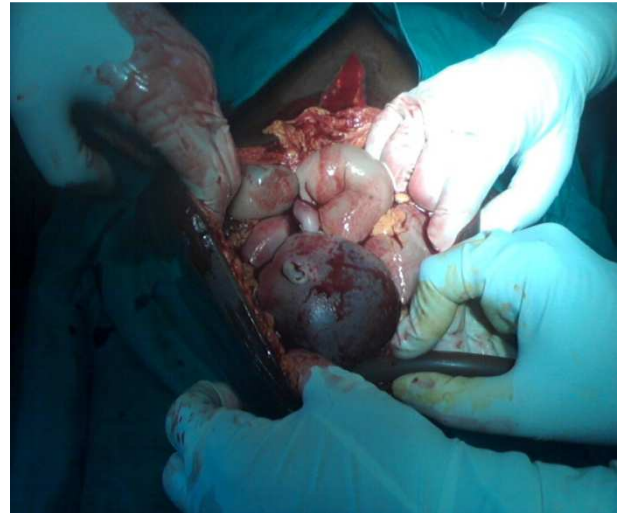2013 at 13h 19 (approximately 4 hours after the accident). On admission, the general condition revealed an obsessed woman, stirred with a Glasgow Coma Scale score at 11, conjunctival pallor with a relatively stable hemodynamic status (Blood Pressure = 11/06 cmhg ; Pulse Rate = 100 bpm , Respiratory Rate = 22 cycles/min). Physical examination revealed a head injury, trauma to the left ankle and hemoperitoneum with strong suspicion of uterine rupture.

Second resuscitative measures have been implemented since her admission and given the relatively stable hemodynamics, an additional assessment was made possible in extreme emergency. At a complete blood count, there was anemia 5.1 g / dl and thrombocytopenia (platelet = 106,000 cells / ml). Renal and liver function tests were normal, prothrombin rate was 53.9 %. Abdominal ultrasound confirmed uterine rupture and also highlighted a splenic rupture. The radiograph of the left ankle noted a bi-malleolar non-displaced fracture supra-ligament, CT cranio-encephalic highlighted a fracture of the cranial vault without mass effect or commitment (Figure 1).



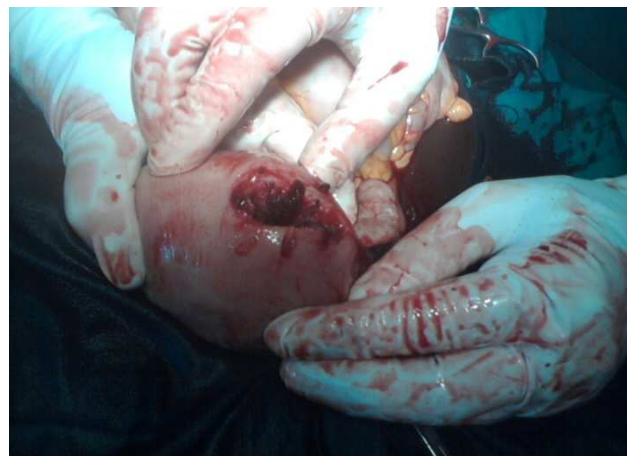**LouéFig 1.tif.** CT cranio-encephalic highlighted a fracture of the cranial vault without mass effect or commitment.

After rapid multidisciplinary consultation (obstetrics, anesthesiology, surgery, emergency and intensivists caregivers), an emergency laparotomy was performed under general anesthesia (induction of anesthesia was started by opioid (fentanyl) and low dose of sodium thiopental, the maintenance of anesthesia was continued by opioid drug), preceded by a fluid and electrolyte resuscitation including a blood transfusion (the patient received a total of 2,5 liters of red blood cells and 3 units of fresh frozen plasma intra and postoperatively).

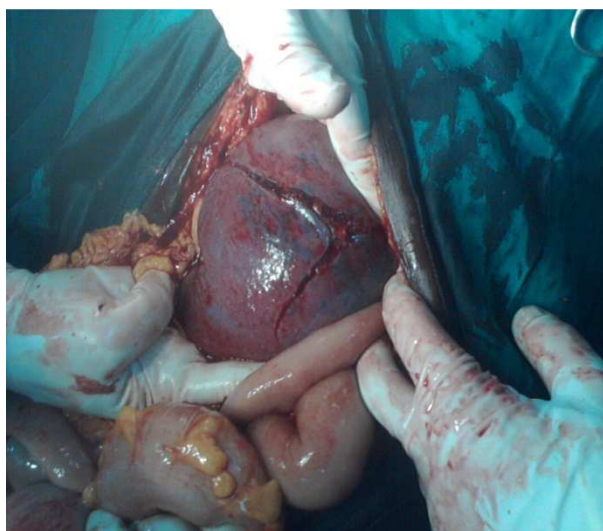


**LouéFig 2.tif.** Intraoperatively, after a midline incision, we found an abundant hemoperitoneum of about 3,5 liters in which bathed a death fetus aged about 28 weeks.

Intraoperatively, after a midline incision, we found an abundant hemoperitoneum of about 3,5 liters in which bathed a death fetus aged about 28 weeks ( Figure 2). Abdominal organs exploration were done that revealed a placenta expelled in part, a complete uterine rupture sit at the fundus of about 8 cm (Figure 3), and a splenic rupture with splenic vascular pedicle injury (Figure 4). Other intra- abdominal organs were intact. We performed a conservative uterine suture and total splenectomy. The left ankle was immobilized in a plaster boot. After the operation, the patient was admitted in intensive care unit. Anti-pneumococcal and Haemophilus vaccination was made for the prevention of infections at the fifteenth day of hospitalization. Postoperative course was uneventful and the patient was discharged on the 19th day of hospitalization and was addressed to neurosurgeon's consultation.



**LouéFig 3.tif.** Intraoperatively, the abdominal organs exploration revealed a complete uterine rupture sit at the fundus of about 8 cm.



**LouéFig 4.tif.** Intraoperatively, it was also noted a splenic rupture with splenic vascular pedicle injury, the splenic lesion was classified as grade IV.

### 3. Discussion

#### 3.1. Frequency of Trauma during Pregnancy

Traumas during pregnancy are not exceptional; however in our country (Cote d'Ivoire), there are no reliable records of accidents and studies on large populations. Only a short series of seven cases resulting in fractures in pregnant women has been reported [5]. In black Anglophone Africa, the rate of pregnant women involved in road accidents was estimated to 0.3 % [6].

In developed countries, traumas affect 6 to 7 % of pregnancies, involved a pregnant woman as a pedestrian of about 4% [1] and they are the leading cause of maternal deaths of non-obstetric origin between the age of 14 and 44 years [1,2]. These injuries are underestimated and represent 55% of non-penetrating abdominal trauma in pregnant women [1,3]. Whether minor or serious, traffic accidents are prone to complications in both the mother and the fetus. The risk of perinatal complications is directly proportional to their intensity and especially the mechanism of abdominal trauma [1,3,4].

#### 3.2. Injuries and Mechanism

The most common obstetric complications frequently observed are miscarriages, threat of premature birth (25 %) which may resolve spontaneously in 90 % of cases and premature rupture of membranes which sometimes exacerbate the threat of premature birth. Placental abruption is one of the most common complications of blunt abdominal trauma. The risk of abruption is 1% to 5 % after minor trauma, but up to 40% to 50 % after severe lesions [4,7]. Fetomaternal hemorrhage involves fetal bleeding into the maternal bloodstream. It is seen in 30 % of severe trauma may be responsible for acute fetal anemia with fetal distress, fetal death and risk of maternal sensitization to Rh-D or other minor antigens [4].

However, uterine rupture and rupture of the spleen observed simultaneously in this pregnant patient appear rarely encountered, even exceptional in highway traffic accident [8-13].

Gravid uterine rupture affects less than 1 % of pregnant women involved in an highway accident [9,12]. Uterine rupture result of direct abdominal impact with high force. The break often is complete and most often involved the fundal region of the uterus with severe symptoms: fetal death is common, maternal prognosis initiated by hemorrhagic shock [10,14] as in the case we describe.

Splenic rupture for its part, would be the most frequent intraperitoneal bleeding lesion during blunt abdominal trauma but is rarely observed during pregnancy [10,11,13]. Indeed, during a closed abdominal trauma to a pregnant woman, the intra-abdominal organs are more or less protected by the gravid uterus which receives preferentially the shock, especially in 2<sup>nd</sup> and 3<sup>rd</sup> trimester of pregnancy.

Splenic rupture is often the result of a direct blow to the rib cage or in the form of bruises supported or occurs on a pathological rate [10, 11, 13, 14]. It may be secondary to abdominal expressions during obstructed labor [11, 15]. In our observation, the splenic rupture was due to direct trauma to the abdomen, the patient was violently struck by a motorcyclist.

Splenic rupture associated with uterine rupture in this patient is particularly unique and potentially fatal by the abundant hemoperitoneum that can cause with increasing maternal breast shock. Splenic rupture testament to the extreme violence of the trauma and appears to have been facilitated not only by the increased vascularity observed during pregnancy but also by the fact that the gravid uterus (relatively small, 28 SA approximately), which should protect the spleen, has itself been broken. This would have fostered the excessive exposure of the spleen at the shock in this type of trauma. In view of the literature, resistance or not of uterus to the traumatic shock and gestational age do not seem sufficient to save lesions of the spleen or other intra-abdominal viscera through direct abdominal trauma. Indeed, any type of intra-abdominal injury may be observed under a severe polytrauma [8, 13].

The fetus is a potential target in trauma during pregnancy. The most common risks factor of fetal death include rarely direct uterine trauma, but is primarily due to placental abruption, maternal hemorrhagic shock (80% fetal death), an high injury severity score > 9, maternal death and uterine rupture responsible for almost 100% of fetal death [4, 12] as in the case we report.

#### 3.3. Approach to the Patient

Generally, the care and supervision of a pregnant victim of a road accident (regardless of gestational age, the seat of the traumatic impact point and the importance of shock) must be performed in a specialized service by a multidisciplinary team. The initial physical examination, given its fundamental forensic significance [12] must be complete and meticulous because clinical symptoms in pregnant women traumatized



may wander due to physiological changes associated with pregnancy.

Primarily, the initial management should be to stabilize the hemodynamic status of the mother first, and then turn attention to the pregnancy and fetus. We must seek and treat maternal vital distress; ensure airway, effective ventilation with oxygen, restore and maintain effective circulation [2,4]. This involves starting early fluid resuscitation knowing that some fluid therapy and some medications are indicated against pregnant women and the expected benefit of medicines should always favor the life of the mother on the fetus.

After initial relative or complete maternal hemodynamic stabilization, a complete physical examination is performed to evaluate specific maternal lesions and assess fetal well-being. In addition to the basic clinical examination, accurate and complete lesion diagnosis and monitoring of pregnant women traumatized necessarily based on a number of additional tests [3,14] including request policy and the organization of the medical team, will make quick and efficient management of the patient .

The abdominopelvic ultrasonography and computed tomography (CT) are at the forefront of para-clinical investigations in this context [7]. Both tests will look for an hemoperitoneum, quantify it and specify the nature of the traumatized organ. In addition, the CT is also essential in the comprehensive assessment of the lesions (whole body) of a polytraumatized patient and allows in the specific case of splenic lesions, to determine the severity score of lesions [16]. Obstetric ultrasound and recording of fetal heart rate (ERCF) will evaluate the consequences of fetal trauma. Laboratory tests conducted in emergency will include especially the rhesus blood group, blood count, the coagulation tests (PT/PTT, and fibrinogen) and Kleihauer-Betke test essential for Rh-negative patients.

In minor or mild trauma with more or less normal initial assessment, hospital care may be needed [3]. Our patient presented a poly- trauma (head trauma with loss of initial knowledge, leg trauma, uterine and splenic rupture), severe anemia requiring blood transfusion and an abundant hemoperitoneum. Given this, a laparotomy was therefore required, which revealed intra- abdominal injuries and treat them. A simple uterine suture was performed because the uterine lesion allowed conservative treatment; however, the splenic lesion classified as grade IV intraoperatively motivated a total splenectomy. However, conservative treatment of the spleen is now recognized as standard treatment because of the persistent risk of infection lifelong of the patients who underwent splenectomy, but we must take into account the predictive criteria for successful conservative treatment [16]. The prevention of these infections relies on anti-bio- prophylaxis whose effectiveness is potentiated by vaccination [14].

## 4. Conclusion

Although relatively rare, trauma in a pregnant woman can have serious consequences for both mother and fetus. Only a

careful physical examination, a good strategy for requesting additional examinations and good organization of the medical team rehearsed for this purpose, can provide rapid and effective management of the patient. However, given the importance of the consequences, it is important to emphasize that prevention is a strict adherence to the rules of the road.

## Author's Contribution

The patient was admitted under the care of Adélaïde Kouassi during this episode. Denis Effoh and Klinna Coulibaly have made the review of the literature for the references. The patient was operated by Védi Loué, Eléonore Gbary, Kacou Yénon and Abdoulaye Ouattara. Védi Loué, Diomandé Gondo and Koffi N'guessan were major contributors in writing the paper. All the authors read and approved the final paper.

## Authors' Affiliation

Diomandé Gondo, Védi Loué, Denis Effoh, Eléonore Gbary, Abdoulaye Ouattara, Klinna Coulibaly and Adélaïde Kouassi are medical doctors. Koffi N'guessan and Kacou Yénon are professors.

## References

- [1] El-Kady D, Gilbert WM, Anderson J, Danielsen B, Towner D, Smith LH. Trauma during pregnancy: an analysis of maternal and fetal outcomes in a large population. *Am J Obstet Gynecol* 2004; 190: 1661-8.
- [2] Mirza FG, Devine PC, Gaddipati S. Trauma in pregnancy: a systematic approach. *Am J Perinatol* 2010; 27 (7):579-86.
- [3] Barré M, Winer N, Caroit Y, Boog G, Philippe H-J. Traumatisme au cours de la grossesse : pertinence des éléments de surveillance dans l'évaluation des suites obstétricales. A propos d'une série de 98 patientes. *J Gynécol Obstét Biol Reprod* 2006 ; 33 : 673-7.
- [4] Corrina M. Oxford, Jonathan Ludmir. Trauma in pregnancy. *Clinical obstetrics and gynecology* 2009,52,4:611-29.
- [5] Kouamé KM, Anoumou NM, Traoré M, Kirioua BJ, Varango GG. Traumatisme et grossesse. Analyse rétrospective d'une courte série de 7 cas au Centre Hospitalier de Treichville (Abidjan-Cote d'Ivoire). *Med Afr Noire* 2009; 56 (6) : 301-4.
- [6] Orji EO, Fadiora SO, Ogunlola IO, Badru OS. Road traffic accidents in pregnancy in southwest Nigeria: a 21-year review. *J Obstet Gynaecol* 2002; 22(5):516-8.
- [7] Bernstein MP. Imaging of traumatic injuries in pregnancy. *Am Coll Radiol* 2008; 26: 23-37.
- [8] Zhu HB, Jin Y. Uterine rupture following a road traffic accident. *Ir J Med Sci* 2011 ;180,3 :745-7.
- [9] Vaysse C, Mignot F, Benezech J-P, Parent O. Rupture utérine traumatique: une complication rare des accidents de la voie publique au cours de la grossesse. A propos d'un cas. *J Gynécol Obstét Biol Reprod* 2007 ; 36 : 611-4.

- [10] Badaoui R, El-Kettani C, Radji M, Samkaoui M-A, Byhet N, Ossart M. Traumatisme de la rate au cours de la grossesse (à propos d'un cas). *Ann Fr Anesth Reanim* 2003 ; 22(8) :736-8.
- [11] Rafanomezantsoa TA, Hariolynirina MOJ, Johannes RF, Zava MA, Rhaerinantenaina F, Andriananpanalinarivo HR, Raveloson NE. Rupture splénique post-traumatique chez une femme enceinte de 36 semaines. *Med Afr Noire* 2013, 60 (8/9) : 373-6
- [12] Vendittelli F, Manciet-Labarchede C, Fabaste JL, Malinas Y. Lésions traumatiques de l'utérus gravide et de son contenu : aspects médico-légaux ; *Rev fr Gynécol Obstét* 1994, 89, 7-9 : 393-400.
- [13] Elbakraoui H, Bouziane H, Akrouch J, Lakdar A, Ferhati D. Rupture de la rate au cours de l'accouchement, à propos d'un cas. *Pan Afr Med J* 2011 ; 9 :21.
- [14] Muller L, Bénézet JF, Navarro F, Eledjam JJ, De la Coussaye JE. Contusions abdominales graves : stratégie diagnostique et thérapeutique. *Encycl Méd Chir*, Elsevier, Paris, Anesthésie-Réanimation, 36-725-C-10,2003, 12p.
- [15] Tribune Libre. Que penser de la pratique de l'expression abdominale en 2008 ? *Gynécol Obstét Fertil* 2008; 36: 1171-4.
- [16] Richardson JD. Changes in the management of injuries to the liver and spleen. *J Am coll Surg* 2005; 200: 648-69.