

Case Report

Ovarian Hyperstimulation Syndrome Due to Exogenous Human Chorionic Gonadotropin (hCG) Presenting More Than 7 Days After hCG Administration

Masaki Kobayashi, Keiichi Kumasawa^{*}, Kaori Koizumi, Tsuyoshi Takiuchi, Hitomi Nakamura, Kenjiro Sawada, Tadashi Kimura

Department of Obstetrics and Gynecology, Osaka University, Suita City, Osaka, Japan

Email address:

kumasawa@gyne.med.osaka-u.ac.jp (K. Kumasawa), kokoko52@hotmail.com (K. Kumasawa)

^{*}Corresponding author

To cite this article:

Masaki Kobayashi, Keiichi Kumasawa, Kaori Koizumi, Tsuyoshi Takiuchi, Hitomi Nakamura, Kenjiro Sawada, Tadashi Kimura. Ovarian Hyperstimulation Syndrome Due to Exogenous Human Chorionic Gonadotropin (hCG) Presenting More Than 7 Days After hCG Administration. *Journal of Gynecology and Obstetrics*. Vol. 5, No. 6, 2017, pp. 78-80. doi: 10.11648/j.jgo.20170506.12

Received: December 6, 2017; **Accepted:** December 23, 2017; **Published:** January 15, 2018

Abstract: We present a case of ovarian hyperstimulation syndrome (OHSS) occurring 8 days after human chorionic gonadotropin (hCG) administration. OHSS is classified as late type if it occurs 12 to 17 days after hCG administration and early type if it occurs within 7 days. Thus, the condition in this patient did not fit the definition of early or late OHSS. The OHSS was mild, and she recovered in approximately 10 days without requiring admission. The patient was not pregnant, and the OHSS was shown to be induced by exogenous hCG administration not endogenous hCG. In conclusion, OHSS can occur 8 to 11 days after hCG administration and it is important to distinguish whether OHSS is induced by endogenous or exogenous hCG.

Keywords: Ovarian Hyperstimulation Syndrome, Chorionic Gonadotropin, Ovarian Cysts, Clomiphene, Infertility

1. Introduction

Ovarian hyperstimulation syndrome (OHSS) is considered a complication of controlled ovarian stimulation (COH) for either *in vitro* fertilization (IVF) or intrauterine insemination (IUI) [1]. OHSS is classified as mild, moderate, or severe depending on the clinical signs and symptoms. Its severe stage, which has a relatively low incidence (0.5 – 5%) among patients undergoing COH, is characterized by massive ovarian enlargement, formation of multiple ovarian cysts, fluid loss into the third space resulting in extravascular fluid accumulation and intravascular volume depletion, coagulation abnormalities, renal failure, hypovolemic shock, and, in rare cases, death [2].

It has been demonstrated that there are two distinct patterns of OHSS, early and late type. The difference between them is the number of days before the onset of OHSS after oocyte pick-up (OPU) or ovulation triggering by human chorionic gonadotropin (hCG) administration. Some studies have

suggested that early OHSS presents between 3 and 7 days after hCG administration and late OHSS occurs 12 to 17 days after hCG administration [3, 4, 5]. Other studies have suggested that early OHSS occurs within 9 days of OPU and late OHSS occurs 10 or more days after OPU [6, 7]. It has been suggested that early OHSS is an acute effect of exogenous hCG administration and is often related to an excessive ovarian response to gonadotrophin stimulation [8]. Conversely, late OHSS is a response to endogenous hCG produced by embryo implantation and is observed only in pregnant women, especially in those with multiple pregnancies [8], and is restricted to cycles in which clinical pregnancy occurs [6]. Late OHSS is significantly more likely to be severe than early OHSS [3, 6, 9]. It is difficult to distinguish early from late OHSS when it occurs 8 to 11 days after hCG administration.

2. Case Report

The patient, a healthy 36-year-old primigravid woman and her partner had a two-year history of infertility of unknown cause. She had regular menses, and a sonohysterogram revealed a normal uterus and patent fallopian tubes. She did not have a history of polycystic ovarian syndrome, and she underwent abdominal enucleatic myomectomy when she was 35 years of age. She was taking no medication and was a non-smoker. The medical history of her husband, a healthy 43-year-old, was unremarkable. The couple underwent treatment with IUI. Ovarian stimulation using clomiphene citrate 50 mg was given from cycle day 7 to 11. On cycle day 14, 5000 IU of hCG was injected with only one dominant follicle measuring 19.5 mm in diameter. IUI was performed 36 hours after hCG administration.

Eight days after hCG administration, the patient presented with symptoms of mild OHSS: abdominal distension, mild lower abdominal pain, and a grossly enlarged right ovary with multiple cysts measuring up to approximately 7 cm (Figures 1 and 2). Her vital signs and weight were stable. Laboratory study results, including hemoglobin, hematocrit, white blood cell count, renal function, and electrolytes were normal.

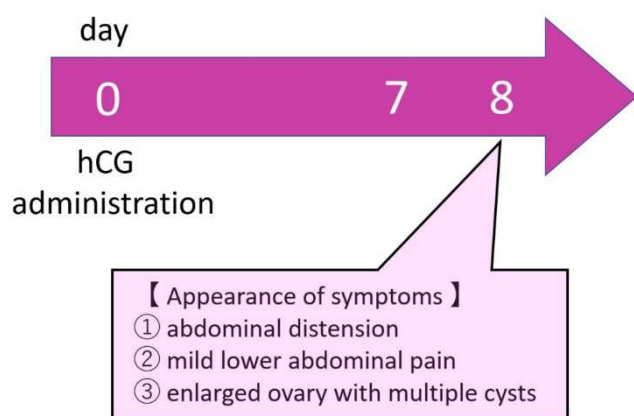


Figure 1. Progress after hCG administration.

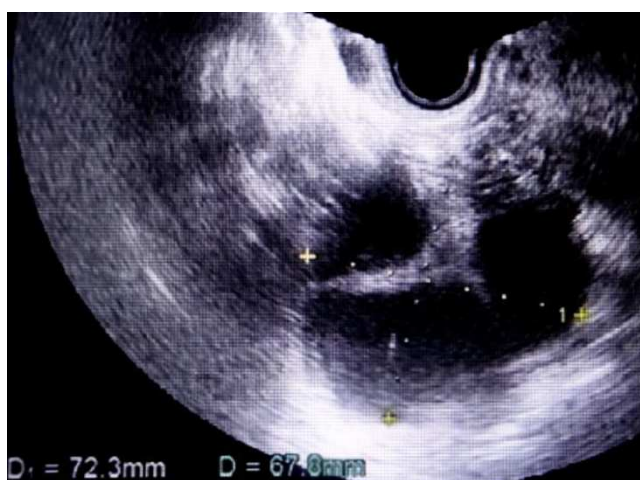

Figure 2. Transvaginal ultrasound images showing markedly enlarged polycystic ovaries. The right ovary measured 72.3 × 67.8 mm.

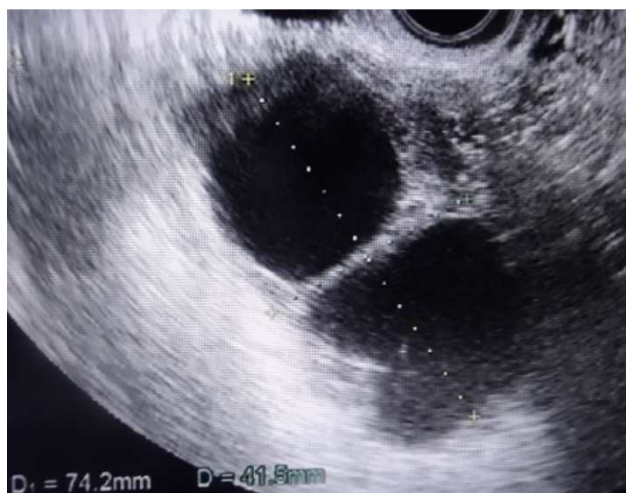

Figure 3. Transvaginal ultrasound images showing reduction in the size of the polycystic ovaries. The right ovary measured 74.2mm × 41.5mm.

The patient required no medication for OHSS. Three days later, her abdominal symptoms had improved, but the sizes of the ovarian cysts were unchanged. Laboratory studies did not show hemoconcentration (hematocrit, 40%, hemoglobin, 129 g/L), leukocytosis (WBC, 7.8×10^9 /L), or hypoalbuminemia (serum albumin, 39 g/L). Four days later, her abdominal symptoms had disappeared, and the ovarian cysts were reduced in size (Figure 3). The serum hCG level was less than 1 IU/L. After four more days, the ovarian cysts had disappeared.

3. Discussion

The physiologic mechanism of OHSS is not yet completely known; however, it is known that the syndrome is characterized by increased capillary permeability with a provocative link to pathologic vasoactive cytokine actions. The clinical features are the consequence of third-spacing of intravascular fluid such as pleuroperitoneal effusions, thromboembolism, and compromised pulmonary or cardiovascular function. To prevent OHSS, we have cancelled induction cycles, discontinued gonadotropin therapy (coasting), decreased the dosage of the hCG trigger, used an agonist trigger, and used embryo cryopreservation. Recently, the use of a vascular endothelial growth factor antagonist has been considered to reduce the early onset and severity of OHSS [10, 11].

In this case, the patient developed OHSS 8 days after hCG administration. She had no symptoms during the first week after hCG administration. Generally, OHSS occurring 8 to 11 days after hCG administration is not precisely defined as early or late. In a small study by Dahl Lyons et al [3], no patients developed OHSS between 8 and 11 days after ovulatory injection of hCG. Because of the timing, it was difficult to determine if the patient had early or late OHSS. However, the serum hCG level 16 days after hCG administration was less than 1 IU/L. This laboratory result and ultrasonography revealed that she was not pregnant. Thus, her OHSS was determined to be a consequence of the exogenous hCG administration. If she had been pregnant, her OHSS might

have been induced by endogenous hCG from the initiated pregnancy. This case underscores the possibility that OHSS due to exogenous hCG can occur more than 7 days after hCG administration.

4. Conclusion

OHSS can occur 8 to 11 days after hCG administration and it is difficult to determine just from the timing if it is early or late OHSS. However, it is important to distinguish whether OHSS is induced by endogenous or exogenous hCG, because OHSS induced by endogenous hCG may be fatal [3] and should be diagnosed and treated as soon as possible. The patient with OHSS occurring 8 to 11 days after hCG administration should be revealed whether she is pregnant or not by her serum hCG level or ultrasonography.

Disclosures

Conflict of Interest: The authors declare no conflicts of interest.

Human and animal rights: This article does not contain any studies with human and animal subjects performed by the any of the authors.

Human rights statement and informed consent: All procedures followed were in accordance with the ethical standards of the responsible committee on human experimentation (institutional and national) and with the Helsinki Declaration of 1964 and its later amendments. Informed consent was obtained from this patient for being included in the study.

Approval by Ethics Committee: The protocol for the research project including human subjects has been approved by a suitably constituted Ethics Committee.

References

- [1] Pereira N, Lekovich JP, Kligman I, et al. Severe ovarian hyperstimulation syndrome after combined GnRH-agonist and low-dose human chorionic gonadotropin trigger in a patient with a single kidney. *Gynecol Endocrinol* 2017; 33: 593-597.
- [2] Keiser UB. The Pathogenesis of the Ovarian Hyperstimulation Syndrome. *N Engl J Med* 2003; 349: 729-732.
- [3] Dahl Lyons CA, Wheeler CA, Frishman GN, et al. Early and late presentation of the ovarian hyperstimulation syndrome: two distinct entities with different risk factors. *Hum Reprod* 1994; 9: 792-799.
- [4] Al-Shawaf T, Grudzinskas JG. Prevention and treatment of ovarian hyperstimulation syndrome. *Best Prac Res Clinical Obstet Gynaecol* 2003; 17: 249-261.
- [5] Lee KH, Kim SH, Jee BC, et al. Comparison of clinical characteristics between early and late patterns in hospitalized patients with ovarian hyperstimulation syndrome. *Fertil Steril* 2010; 93: 2274-2280.
- [6] Mathur RS, Akande AV, Keay SD, et al. Distinction between early and late ovarian hyperstimulation syndrome. *Fertil Steril* 2000; 73: 901-907.
- [7] Korhonen K, Savolainen-Peltonen H, Mikkola T, et al. C-reactive protein response is higher in early than in late ovarian hyperstimulation syndrome. *Eur J Obstet Gynecol Reprod Biol* 2016; 207: 162-168.
- [8] Papanikolaou EG, Tournaye H, Verpoest W, et al. Early and late ovarian hyperstimulation syndrome: early pregnancy outcome and profile. *Hum Reprod* 2005; 20: 636-641.
- [9] Elena P, Isabel AM, Raul G, et al. Plasma levels of soluble vascular endothelial growth factor receptor-1 may determine the onset of early and late ovarian hyperstimulation syndrome. *Hum Reprod* 2006; 21: 1453-1460.
- [10] Alper MM, Smith LP, Sills ES. Ovarian hyperstimulation syndrome: current views on pathophysiology, risk factors, prevention, and management. *J Exp Clin Assist Reprod* 2009; 6: 3.
- [11] Jellad S, Haj HA, Basly M, et al. Vascular endothelial growth factor antagonist reduces the early onset and the severity of ovarian hyperstimulation syndrome. *J Gynecol Obstet Hum Reprod* 2017; 46: 87-91.