

Case Report

Mature Ovarian Teratoma and Pregnancy About a Case in Abidjan Cote d'Ivoire

Eleonore Gbary-Lagaud¹, Denis Effoh¹, Assemien Ehui², Soh Koffi¹, Carine Houphouet-Mwandji¹, Roland Adjoby¹

¹Teaching Hospital Center of Angre, Mother and Child Department, Felix Houphouet Boigny University, Abidjan, Cote d'Ivoire

²Pathological Anatomy Histology Embryology Cytogenetics Department, Felix Houphouet Boigny University, Abidjan, Cote d'Ivoire

Email address:

eleonoregbary@gmail.com (E. Gbary-Lagaud)

To cite this article:

Eleonore Gbary-Lagaud, Denis Effoh, Assemien Ehui, Soh Koffi, Carine Houphouet-Mwandji, Roland Adjoby. Mature Ovarian Teratoma and Pregnancy About a Case in Abidjan Cote d'Ivoire. *Journal of Gynecology and Obstetrics*. Vol. 8, No. 4, 2020, pp. 117-121.

doi: 10.11648/j.jgo.20200804.19

Received: July 23, 2020; **Accepted:** August 5, 2020; **Published:** August 20, 2020

Abstract: As part of the optimization of care, ultrasound scans are routine during pregnancy. The result is the more frequent finding of a benign-looking tumor associated with pregnancy. These are most often mature teratomas of the ovary also called dermoid cyst. We report a case of mature ovarian teratoma larger than 60 mm, diagnosed in early pregnancy. The objective of this clinical case is to discuss the pathophysiological mechanisms, prognosis and management in countries under medical care. This case occurred in a primigest, nulliparous 28-year-old woman who did not have a specific medical history. The pregnancy was brought to term without major complications. The mode of delivery was a cesarean section, which gave us the opportunity to perform the cystectomy. In view of this case, we propose that, in the absence of a laparoscopy or a laparotomy for an ovarian cyst associated with pregnancy and when the maternal-fetal condition allows it, therapeutic abstention may be considered. In this case, special prenatal monitoring must be carried out by a multidisciplinary team of obstetrician, sonographer, intensive care anesthesiologist and neonatologist. Apart from complications directly related to the cyst during pregnancy, we recommend a full term caesarean section. This represents an opportunity to perform the cystectomy at the same time of operation.

Keywords: Mature Ovarian Teratoma, Pregnancy, Ultrasound

1. Introduction

The quality requirements of good medical practice recommend, as part of prenatal follow-up, the performance of ultrasound in each trimester of pregnancy. The result is the discovery of more and more ovarian tumors associated with pregnancy [1, 2]. Most often they are benign: mature teratomas of the ovary or dermoid cysts [3]. The combination of potentially benign tumor and pregnancy is above all a problem of surveillance. But it also raises questions of the way, the end of the delivery and the care.

We report a case of a mature ovarian teratoma diagnosed early in a pregnancy that was brought to term. The aim is to discuss the pathophysiological mechanisms, prognosis and management in countries under medical care.

2. Case Presentation

It was a 28-year-old patient with a primigravidae with no particular medical history. She consulted for a 10-week secondary amenorrhea associated with pelvic pain. Clinical examination suspected an intrauterine pregnancy associated with a laterouterine mass. Obstetric pelvic ultrasound confirmed the single intrauterine pregnancy as well as the presence of a right ovarian tissue formation, multicloisonate with calcifications, without intracystic adenoids measuring 96 mm x 60 mm suggesting a dermoid cyst (Figure 1). A close prenatal follow-up plan was put in place with the performance of an ultrasound for a monthly monitoring of the fetus and especially of the cyst. The signs in favor of a cyst complication were explained to the patient (persistent acute

abdominal pain, easy vomiting, cessation of materials and gas). The course was marked by the occurrence of sharp and acute abdominal pain at 29 weeks of amenorrhea (WA), raising fears of twisting of the cyst. These pains were rather related to a distension of the wall of the cyst. The management consisted of ice packs, analgesics and anti-inflammatory drugs administered on an ad hoc basis. The pregnancy continued with an enlargement of the ovarian cyst to 128 mm x 93 mm. An indication for an elective caesarean has been made. Transverse segmental caesarean section extracted a healthy 2 600g newborn at 37 weeks with an APGAR of 8-9. After hysterorrhaphy, the second operative stage consisted of cystectomy (Figures 2, 3). Abdominal exploration did not find ascites or granulations and the contralateral ovary was healthy. Macroscopically the cyst measured 127 mm x 107 mm per 500 g and had a creamy whitish, milky liquid appearance containing hair and teeth (Figure 4). Histological examination revealed a mature teratoma of the ovary (Figure 5).

the authors, the frequency varies between 22% and 50% of benign ovarian tumors during pregnancy [1, 4, 5]. This tumor most often affects women of child-bearing age [2, 6, 7].

Mature ovarian teratomas are thought to be of parthenogenetic origin [8]. In fact, a pluripotent stem cell or a primordial germinal cell before meiosis I of oocytes would be the starting point of mature ovarian teratomas [9]. Thus, mature teratomas result from the proliferation of immature cells from the three embryonic layers: endoderm, mesoderm and ectoderm [10].

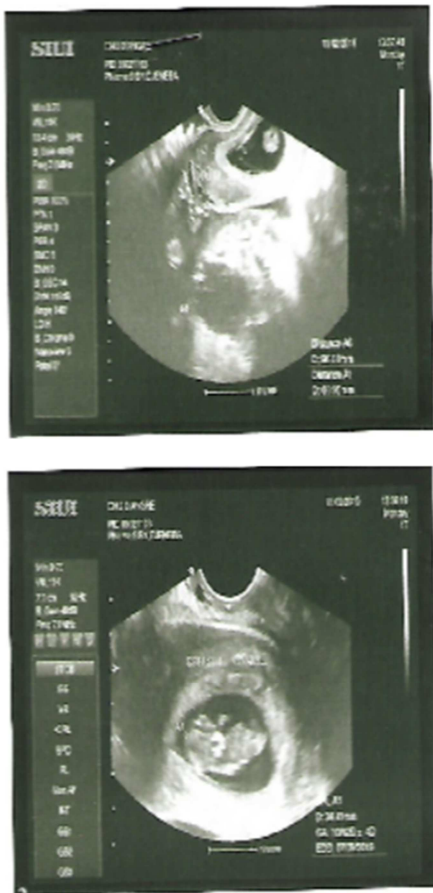

Figure 1. Obstetric ultrasound Progressive pregnancy of 10 weeks associated with a right ovary cyst of 96 mm x 60 mm.

3. Discussion

3.1. Physiopathology

Benign ovarian tumor pathology during pregnancy is dominated by dermoid cysts or mature teratoma. According to

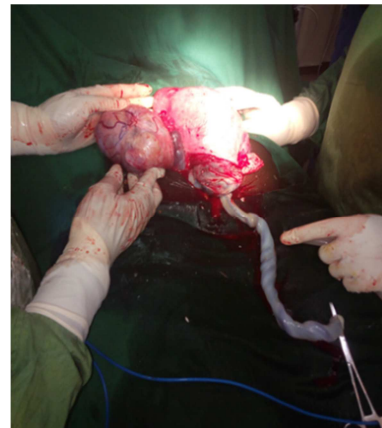

Figure 2. Right ovarian cyst after fetal extraction.

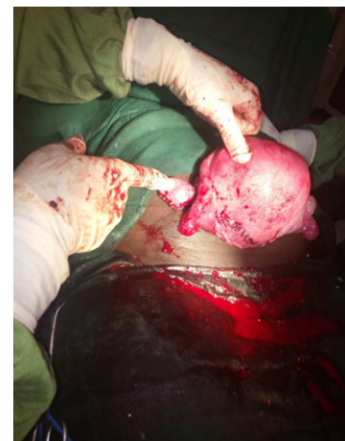

Figure 3. Right ovary after cystectomy.

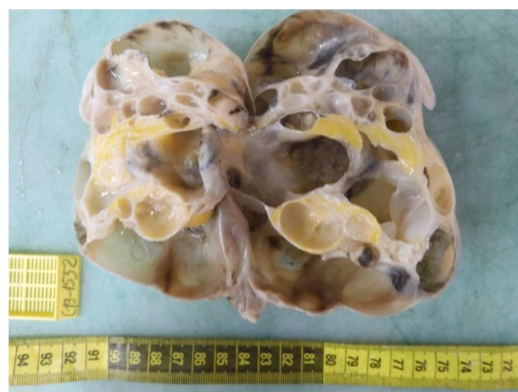


Figure 4. Macroscopic appearance of a multilocular and septate ovary cystic with the presence of hairs.

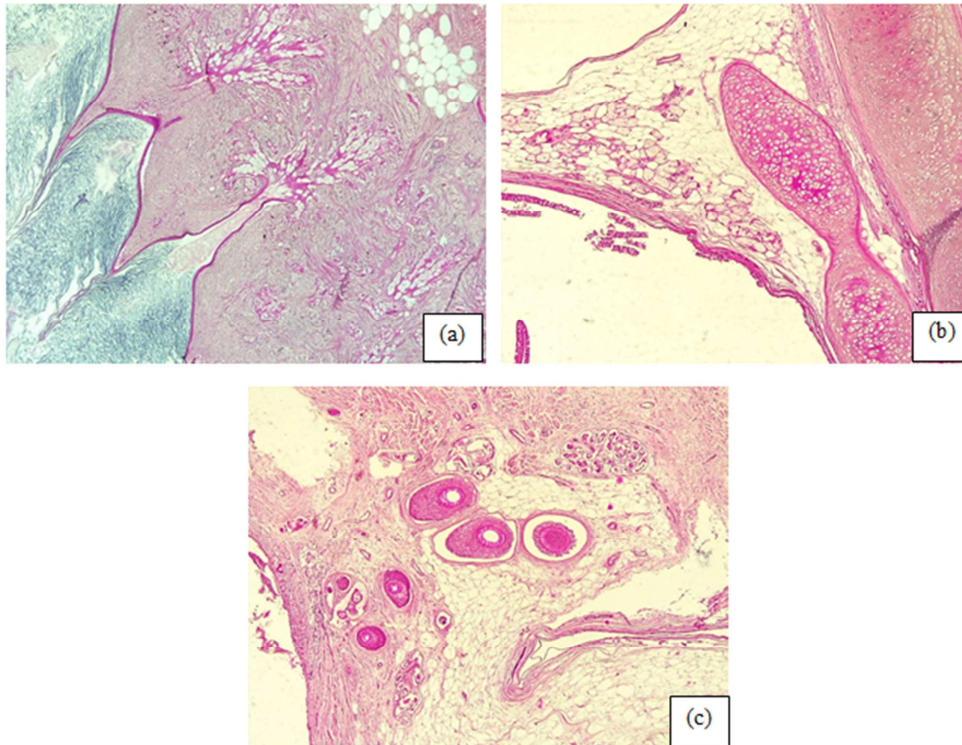


Figure 5. Histology Mature Teratoma of the Ovary (Hematein-Eosin HEx4); (a) Presence of keratin lamellae, sebaceous glands, and adipocytes respectively in the lumen and the cystic wall, (b) Presence of pilosebaceous follicle and adipocytes in the cystic wall, (c) Presence of cartilage tissue in the cyst wall.

3.2. Diagnosis

Benign ovarian tumors are most often of low clinical expression. These tumors are increasingly diagnosed early and incidentally during pregnancy due to the popularization of ultrasound. Pregnancy can lead to a diagnostic delay by an ascension of the tumor which then becomes extra pelvic due to the gravid uterus [4]. In our case there were no diagnostic difficulties. The diagnosis was early at the 10th week of amenorrhea with a cyst initially exceeding 60 mm. Certainly, this existed before the pregnancy and remained asymptomatic as is often the case [2, 10].

Ultrasound remains the key examination for the diagnosis of ovarian tumors associated with pregnancy [11]. The following ultrasound criteria are necessary to suggest the benign nature of the tumor. These are among others: a regular homogeneous image, anechoic fluid content with posterior reinforcement; a thin and regular wall (<3 mm) without partition or intracystic vegetation; a diameter of less than 80 mm; lack of blood supply or peripheral blood supply on color Doppler and a high pulsatility index [1]. The presence of a cystic ovarian formation with an echogenic nodule hanging from the wall (Rokitansky's nodule) is strongly suggestive of a mature teratoma [6]. Magnetic resonance imaging (MRI) would provide additional information when ultrasound is not relevant enough [1, 4, 6, 11]. Since MRI is not a common practice in our under medicalized context, it was not performed in our case. In addition, the ultrasound clearly revealed the benign features of the ovarian tumor.

Serum marker assays CA125 and alpha foeto protein (AFP) are of no interest in pregnant women [1, 12]. Indeed, CA125 is

physiologically increased during pregnancy and does not constitute a diagnostic aid in pregnant women [1]. Changes in AFP may raise suspicion of fetal disease as part of an antenatal diagnosis.

3.3. Prognosis

There is a high risk of complications from ovarian cysts associated with pregnancy when these measure more than 60 mm [1, 13]. The main acute complications of ovarian cysts in pregnancy are adnexal torsion, cyst rupture, intracystic hemorrhage, and praevia cyst [12]. One of the most dreadful is the adnexal torsion. In fact, adnexal torsion manifests itself as abdominal pain syndrome. If this is not taken care of, it can lead to ovarian necrosis, which will be followed by ovarian superinfection. In our case, the patient presented acute abdominal pain syndrome at the 29th WA. This was due to the rapid growth of the cyst, growing by 28 mm in 19 weeks. This rapid growth contributed to creating an overdistension of the cyst wall in places, responsible for the pain. In fact, the growth of mature teratomas of the ovary is slow, ie 1.8 to 2 mm per year outside pregnancy [2, 10]. However, hormonal changes induced by pregnancy may be responsible for the rapid increase in the size of dermoid cysts [3, 4, 14]. In fact, mature teratomas are believed to have estrogen and progesterone receptors [14]. These hormones stimulate the growth of the sebaceous glands contained in mature teratomas [10]. This explains their faster growth during pregnancy where the secretion of these hormones is increased (estrogen from 0.55 nmol/l to 110 nmol/l; progesterone from 1.5 nmol/ml to 700 nmol/l).

3.4. Treatment

The problem of the management of dermoid cysts associated with pregnancy arises for those over 60 mm. Some more reservist writers recommend abstention [4, 15]. Other more interventionist authors recommend laparoscopy until 16-17 WA, beyond an open laparoscopy or a laparotomy seem more indicated [1, 12, 16, 17]. Laparoscopy can be performed up to 22 WA depending on the experience of the operators [1]. In all cases it is important to take into account the risk benefit balance. Laparoscopy during pregnancy is not without risk. The pneumoperitoneum necessary for its realization is thought to be the cause of hypoxia and fetal acidosis [1]. In addition to the anesthetic risks, there are the risks inherent in pregnancy, namely termination of pregnancy, especially in the first and second trimester, and thromboembolic events [1, 4]. The size of the cyst greater than 60 mm in our case should probably have motivated a cystectomy from the start, if only by laparoscopy. However, the cost of this first look remains high in developing countries. In addition, we did not want to jeopardize the course of the pregnancy. In our case, the rapid evolution of the size of the cyst during pregnancy motivated the cesarean section and the cystectomy at term. This in view of complications including possible rupture of the cyst during childbirth due to abdominal thrusts.

Premature deliveries, newborns small for gestational age, neonatal and neonatal deaths are also more frequent in the association of ovarian cyst and pregnancy [1]. In our case the weight of the newborn was in harmony for the gestational age.

As a therapeutic alternative to surgery, some authors propose a guided echo puncture of the dermoid cyst [2]. However, the high risk of recurrence (between 30 and 50%) and the risk of chemical peritonitis does not make this option a satisfactory alternative [2].

4. Conclusion

The chance discovery of ovarian cysts during pregnancy is more common. The ultrasound is efficient enough to point to the benign nature of the ovarian cyst. The issue of care exists for cysts over 60 mm. In the absence of a laparoscopy or laparotomy for an ovarian cyst associated with pregnancy and when the maternal-fetal condition allows it, therapeutic abstention can be considered. In this case, special prenatal monitoring must be done. In the absence of complications directly related to the cyst, we recommend a cesarean section at term. This represents an opportunity to perform the cystectomy at the same time of operation for a pathological examination.

Conflict of Interest

All the authors do not have any possible conflicts of interest.

Author's Contributions

All authors were major contributors in writing the paper. All authors read and approved the final paper.

Ethical Approval

The study was approved by the Houphouët-Boigny's University ethics committees.

References

- [1] Bricou A, Demaria F, Antonetti E, Jouannic JM, Benifla JL. Prise en charge des kystes ovariens en cours de grossesse. Collège National des Gynécologues et Obstétriciens Français. Extrait des Mises à jour en Gynécologie Médicale 2006 publié le 29.11.2006: 270-80.
- [2] Naveau A, Panel P. Chirurgie annexielle et grossesse: indications, voies d'abord et techniques. Centre hospitalier de Versailles - Hôpital A. Mignot - 177 rue de Versailles -78150 Le Chesnay: 471-88.
- [3] Schreck AM, Mikdachi HF. Benign Ovarian Tumors in Pregnancy: A Case Report of Metachronous Ipsilateral Recurrent Mucinous Cystadenoma in Initial Pregnancy and Mature Cystic Teratoma in Subsequent Pregnancy. Cureus January 03, 2019, 11 (1): e3818. DOI 10.7759/cureus.3818.
- [4] Hélage S, Borghese B, Depinay C, Millischer-Bellaïche AE, Alexandre J, Chopin N. Tératome immature de l'ovaire en cours de grossesse. Presse Med. 2011; 40 (1P1): 102-5.
- [5] Tarriel O, Huissoud C, Rudigoz RC, Dubernard G. Tumeurs ovariennes présumées bénignes lors de la grossesse. Journal de gynécologie obstétrique et biologie de la reproduction 2013, 42: 842-55.
- [6] Damarey B, Farine MO, Vinatier D, Collinet P, Lucot JP, Kerdraon O, Poncelet E. Tératomes ovariens matures et immatures: caractéristiques en échographie, TDM et IRM. Journal de Radiologie, Janvier 2010; 1 (91): 27-8.
- [7] Iman Fayez, Basel Khreisat, Tarek Athamneh, Reema Omoosh and Mayada A. Daibes. Multiple Bilateral Ovarian Mature Cystic Teratomas with Ovarian Torsion: A Case Report. Oman Medical Journal 2018; 33 (2): 163-6. DOI 10.5001/omj.2018.30.
- [8] Khan N, Sen Ray P, Hakim S, et al. Retinal tissue in mature cystic teratoma of ovary presenting with full-term pregnancy. BMJ Case Rep 2014; 1-3. Doi: 10.1136/bcr-2013-202914.
- [9] Wen-Chung Wang, Yen-Chein Lai. Genetic analysis results of mature cystic teratomas of the ovary in Taiwan disagree with the previous origin theory of this tumor. Hum Pathol 2016 Jun; 52: 128-35. doi: 10.1016/j.humpath.2016.01.011. Epub 2016 Feb 5.
- [10] Kathleen E, O'Neill, and Cooper AR. The Approach to Ovarian Dermoids in Adolescents and Young Women. J Pediatr Adolesc Gynecol. 2011 June; 24 (3): 176-80.
- [11] Haddad S, Selleret L, Fedida B, Benjoar M, Beljord S, Thomassen-Naggarra I, Bazot M. Masses annexielles et grossesse: quelle imagerie et quels diagnostics ? Imagerie de la femme 01 Juin 2017; 2 (27): 104-10.

- [12] Sachchidananda M, Zamurrad F, Anjum ZK and Hopkins RE. Ruptured ovarian cystic teratoma in pregnancy with diffuse peritoneal reaction mimicking advanced ovarian malignancy: a case report. *Journal of Medical Case Reports* 2008, 2: 203 doi: 10.1186/1752-1947-2-203.
- [13] Hasson J, Tsafirir Z et al. Comparison of adnexal torsion between pregnant and non-pregnant women. *Am J of Obstet and Gynecol* June 2010: 536. e1-536. e6.
- [14] Liang-Hsuan Chen, Shuenn-Dhy Chang, Hong-Yuan Huang, Hsin-Shih Wang, Yung-Kuei Soong, Hsien-Ming Wu. Repeated pregnancy with concomitant presence of ovarian teratoma: A case report and literature review. *Taiwanese Journal of Obstetrics & Gynecology* 2017; 56: 694-6.
- [15] Marret H. Doppler ultrasonography in the diagnosis of ovarian cysts: indications, pertinence and diagnostic criteria. *J Gynecol Obstet Biol Reprod* 2001; 30 (1): S20-33.
- [16] Afaf A, Felemban, Zuha A, Rashidi, Musab H, Almatrafi, and Jawaher A. Alsahabi. Autoimmune hemolytic anemia and ovarian dermoid cysts in pregnancy. *Saudi Med J.* 2019; 40 (4): 397–400. doi: 10.15537/smj.2019.4.24107.
- [17] Apostolakis-Kyrus K, Indermaur MD, Prieto J. Teratoma in Pregnancy: A Case Report. *J Reprod Med.* Sep-Oct 2013; 58 (9-10): 458-60. PMID: 24050039.