

Post Caesarean Uterine Scar Dehiscence: A Case Report and a Short Review of Literature

Gunjan Bahuguna^{*}, Naheeda Shaikh, Ashok Anand, Pratyasha Swain, Rajashree Thatikonda

Department of Obstetrics and Gynaecology, Grant Medical College and Sir Jamshedjee Jeejeebhoy Group of Hospitals, Mumbai, India

Email address:

drgunjanjjh@gmail.com (G. Bahuguna)

^{*}Corresponding author

To cite this article:

Gunjan Bahuguna, Naheeda Shaikh, Ashok Anand, Pratyasha Swain, Rajashree Thatikonda. Post Caesarean Uterine Scar Dehiscence: A Case Report and a Short Review of Literature. *Journal of Gynecology and Obstetrics*. Vol. 10, No. 4, 2022, pp. 176-182.

doi: 10.11648/j.jgo.20221004.12

Received: June 1, 2022; **Accepted:** July 4, 2022; **Published:** July 13, 2022

Abstract: There has been a rise in lower segment caesarean sections in modern obstetrics with the prevalence being 21.5% in India according to NFHS-5. With the rise in LSCS, there has been also been a rise in risks and complications associated with it. We are going to discuss one such complication of infected uterine incisional necrosis and dehiscence after caesarean delivery, and a brief review of risk factors, pathophysiology and the management of this postpartum complication. Diagnosis can be done using methods such as ultrasonography, magnetic resonance imaging, and computer-aided tomography. Treatment includes resuturing the uterine incision line, hysterectomy, or conservative treatment accompanied by broad-spectrum antibiotics administration. We evaluated 2 cases one of which presented as puerperal sepsis and was diagnosed with the help of USG and CT and was surgically managed by debridement of infected and necrosed tissue and reconstruction of uterine rent along with broad spectrum antibiotics. The other case presented to us as puerperal sepsis, secondary post-partum hemorrhage and acute kidney injury that was diagnosed by ultrasound as a dehiscence scar postpartum after caesarean section and was managed surgically by obstetric hysterectomy. Both the cases were high risk and required prompt diagnosis and management. A study of various presentation of post caesarean uterine scar dehiscence and the methods of management is been discussed so as to aid in prompt diagnosis and appropriate management can be done with good outcomes. Post Caesarean uterine scar dehiscence can be managed conservatively or surgically, tailored to the patient attributes with a good outcome.

Keywords: Uterine Scar Dehiscence, Puerperal Sepsis, Postpartum Haemorrhage, Uterine Necrosis, Puerperal Pyrexia, Heavy Vaginal Bleeding Postpartum, Post Caesarean Uterine Scar Dehiscence, Complications of Caesarean Section

1. Introduction

There has been a rise in lower segment caesarean sections in modern obstetrics with a prevalence of 21.5% in India according to the National Family Health Survey-5 in 2019-21. With the rise in caesarean sections, the associated complications have also risen, such as post-partum infections, secondary haemorrhage, risk of postoperative uterine scar dehiscence and need for second-stage hysterectomy. Long term sequelae include recurrent low lying placenta in the subsequent pregnancies, placental adhesion anomalies, chronic pelvic pain, pelvic adhesions, and menstrual disorders [1-3]. It has been seen that post-caesarean uterine scar dehiscence is rare, accounting for about

0.06% - 3.8% [4]. Post-caesarean uterine scar dehiscence can be diagnosed by ultrasonography with magnetic resonance imaging or computer-aided tomography which can reveal anatomy in detail. Treatment includes starting broad-spectrum antibiotics and surgical options in cases unresponsive to conservative measures. Laparotomy is performed in cases of severe infection [6, 7] and includes debridement of the infected uterine tissue with resuturing of the dehiscence uterine scar or hysterectomy in cases with endomyometritis or abscess formation [5, 8]. 2 cases of postpartum uterine scar dehiscence have been described with who were managed surgically by conservative and definitive methods. A detailed review of similar case reports has been done to study the various presentations and the appropriate management.

2. Material and Methods

We reviewed 17 cases in various studies and case reports searched from the Pubmed database with keywords “uterine

scar dehiscence”, “post caesarean uterine scar dehiscence”, and “post-caesarean uterine necrosis” and “post caesarean complications” and the studies have been briefly summarised in Table 1.

Table 1. Review of the recent case reports with post caesarean uterine scar dehiscence.

Sr No	Study	Year	Indication for LSCS	Day of Presentation	Presenting complain	Risk factor
1	Treszezamsky et al [13]	2011	second stage arrest	day 3	fever wound infection	gestational hypertension
2	Sengupta et al [6]	2012	Previous 2 LSCS	8 weeks	postpartum bleeding	Previous 2 LSCS with thinned out scar
3	El- Agwany [5]	2014	P1L1	3 weeks	abdominal pain and vaginal discharge	fluid in uterus with dehiscence uterine scar
4	El- Agwany [5]	2014	P1L1	2 weeks	abdominal pain and vaginal discharge	
5	El- Agwany [5]	2014	P1L1	2 weeks	abdominal pain and vaginal discharge	
6	El- Agwany [5]	2014	PROM with infertility conception with triplet pregnancy	5th day	vaginal haemorrhage with purulent discharge	PROM with elderly primigravida
7	Chaudhary et al [20]	2014	Previous 2 LSCS	9th day	fever, abdominal pain	previous 2 LSCS with thinned out scar
8	Ida [8]	2014	low lying placenta	6 months	persistent menstrual bleeding for 1 month	low lying placenta
9	Alwani [3]	2014	transverse lie, PROM	11th day	fever, chills, rigor, abdominal distension, vaginal discharge	previous 2 LSCS with thinned out scar
10	Bharatam [21]	2015	Deep transverse arrest with fetal distress		fever, tachycardia, wound sepsis with pus discharge	
11	Nigam [18]	2016	P1L1 with 2nd stage arrest	2nd day	fever, foul smelling discharge from suture site, burst abdomen	
12	Dedes [19]	2016	P1L1 with NPOL	2nd day	fever	previous 2 LSCS with thinned out scar
13	Badr [14]	2017	P5L5 with fetal distress	10th day	fever, vaginal discharge	
14	Aggarwal [17]	2019	P2L2A1 for previous 2 LSCS	42nd day	heavy vaginal bleeding	
15	Zhang [10]	2020	P2L2A1 for previous 2 LSCS	3 months	heavy vaginal bleeding	previous LSCS
16	Chavan [22]	2020	p2L2 for previous 2 LSCS	day 14	abdominal pain, fever, chills	diabetes mellitus
17	Thakur [15]	2021	p2L2, not willing for trial of labor	day 44	heavy vaginal bleeding	anaemia
18	Case report 1	2021	p1L1, with fetal distress	Day 1	Fever and breathlessness	Previous 1 LSCS
19	Case report 2	2021	P2L2	Day 1	Primary Post-partum haemorrhage with thrombocytopenia and low urine output	

Table 1. Continued.

Sr No	USG/CT	Blood Transfusion	Treatment	Post- op	Organisms
1	heterogenous air and fluid collection between bladder and uterus		conservative surgical management	uneventful	streptococcus angiosus
2	ET-13mm,	6 PRC and 4 FFP	hysterectomy	uneventful	E. coli
3	dehiscence in lower uterine segment with hematoma 10 cm collection in parietal wall		conservative medical management	uneventful	
4	uterine scar dehiscence and hematoma in uterovesical pouch of 5 cm		conservative medical management	uneventful	
5			conservative medical management	uneventful	
6	sub voluted with fluid intrauterine pelvic collection bulky uterus with widened endometrial canal 2.2cm	2 PRC 2 FFP	hysterectomy	uneventful	
7	with uterine wall defect and organised collection of 9.3x 2.5 cm	3 PRC 6 FFP	hysterectomy	uneventful	E. coli
8	20x 15mm uterine scar dehiscence		conservative saline lavage	uneventful	
9	collection in POD		conservative surgical management	uneventful	
10	collection in POD		conservative surgical management	uneventful	S. aureus
11		2 PRC	conservative surgical management f/b Hysterectomy	uneventful	
12	collection of fluid at uterine incision		abscess drainage with negative pressure wound treatment	uneventful	E. coli
13	5x3x3cm anterior uterine wall collection, 5x 4x 3 cm collection in POD		conservative surgical management	uneventful	proteus mirabilis
14	hyperechoic collection of 2x 3 cm at fundus	multiple blood transfusions	hysterectomy	uneventful	E. coli and acinetobacter
15	TVS- ET-0.7	4 PRC 4 FFP	hysterectomy	uneventful	
16	free fluid in pelvis with discontinuity of anterior uterine wall		hysterectomy	uneventful	MRSA

Sr No	USG/CT	Blood Transfusion	Treatment	Post- op	Organisms
17	2x2cm hyperechoic lesion in POD	5 PRC, 1 FFP, 2 RDP, 3 cryoprecipitate	hysterectomy	uneventful	
18	Mild chronic septic collection in POD, beneath the suture site and pre-peritoneally, suture site uterine dehiscence	1 whole blood and 4 FFP, 1 PRC	Conservative surgical management	Uneventful	
19	Bulky uterus with intrauterine hematoma, mild ascites with B/L kidneys with raised cortical echogenicity	4 PRC, 8 FFP, 1 SDP	Hysterectomy	Uneventful	

2.1. Case Report 1

A 24-year-old lady, para 1 living 1 Day 22 post LSCS was referred from a peripheral hospital with sepsis. She had been febrile since Day 1 post-op and had breathing difficulty for the past 10 days. She had been investigated for the cause of infection and blood culture reports showed aerobic gram-positive bacteria sensitive to Linezolid. Haemoglobin was 8.4g/dl, leukocyte count of 12800/dl (neutrophil count of 78%) and platelet count of 351000/dl, C Reactive Protein was raised (105); fever profile was negative for malaria, dengue, typhoid and urine culture showed candida species. Ultrasonography of the abdomen revealed anterior uterine wall fibroid, mild hepatomegaly and ascites. The patient had been given injectable linezolid 500 mg twice a day for 7 days along with injectable antipyretics but her symptoms did not resolve so she was referred to a tertiary care centre.

She came to us as a sick looking patient, with a fever of 102 degrees Fahrenheit, moderate pallor, tachycardia of 140 bpm and blood pressure of 100/60 mmHg. Her per abdomen examination revealed a healthy suture line with a soft abdomen and a palpable uterus. Per speculum vaginal examination showed scanty, foul-smelling lochia and on per vaginal examination, her vagina was tender and hot with a uterine size of 14 weeks.

We started her on broad spectrum injectable antibiotics (injection Ceftriaxone 1 gm twice daily and injection metronidazole 100cc thrice daily) and fresh blood investigations showed her Haemoglobin- 8.9 g/dl, leucocyte count- 12300/dl (neutrophil- 76%) platelet count- 282000/dl, normal electrolytes, prothrombin time- 20.1 secs and INR- 1.51, creatinine level of 1 mg/dl. A septic bundle (malaria/ typhoid/ dengue) was sent which came out to be negative. Ultrasonography of the abdomen was suggestive of mild chronic septate collection in the POD and a bulky uterus consistent with postpartum status and an endometrial thickness of 8 mm. CT scan of the pelvis was suggestive of suture site uterine dehiscence, chronic collection in the POD, beneath the suture site and pre-peritoneally (Figure 1).

The patient was taken up for emergency exploratory laparotomy for uterine dehiscence. Intra-operatively around 500-600ml of straw-coloured foul-smelling fluid was drained, and full length uterine lower segment scar dehiscence with necrosed edges was found (Figure 2). Peritoneal slough and necrotic debris were collected and necrosed edges were removed and sent for culture sensitivity, followed by uterine rent suturing (Figure 3). A thorough peritoneal lavage with 1 litre of normal saline was done and an abdominal drain was inserted. Intraoperatively 1 whole blood and 4-pint fresh frozen plasma were transfused and the patient was shifted to

the critical care unit for observation. However, the abdominal fluid culture reports did not reveal any organism. Post laparotomy she developed multiple febrile episodes and developed an abdominal wound gape (Figure 4). Daily dressing of the wound was done for about 5 days and she was taken up for resuturing on day 12 of laparotomy. However, she continued to have fever spikes for which repeat blood investigations were sent. Her blood investigations showed her haemoglobin as 7 grams/dl, leucocytes of 28000 and platelets of 1.5 lakh. Repeat ultrasonography of the abdomen showed a chronic multiloculated collection in the POD extending up to the hepatic capsule. She was started on injection meropenem 1 gm twice daily and a culdotomy for evacuation of the collection was planned. A culdotomy was performed and a 22 French Foley catheter was left in the culdotomy site to keep the collection draining. Post-culdotomy she had no fever spikes and her general condition improved. The culture of the culdotomy collection was not suggestive of any organism. After 5 days, the culdotomy draining Foley catheter was removed and the patient was discharged. She was followed up after a month telephonically and is doing well.

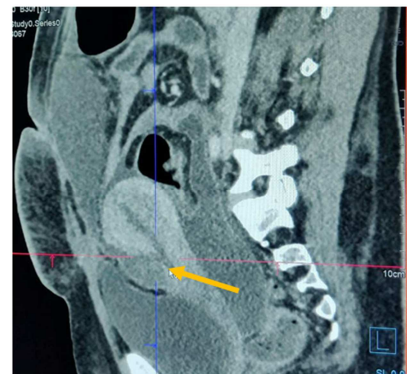


Figure 1. CT scan image suggestive of suture site uterine dehiscence (marked by arrow), chronic collection in POD and collection beneath the suture site and pre-peritoneally.

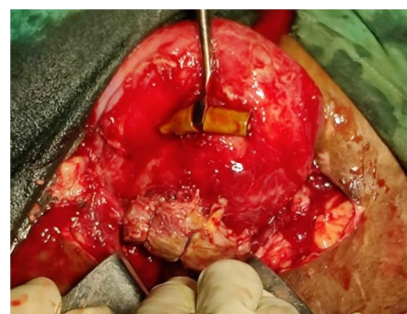


Figure 2. Full length uterine lower segment scar dehiscence with necrosed edges.

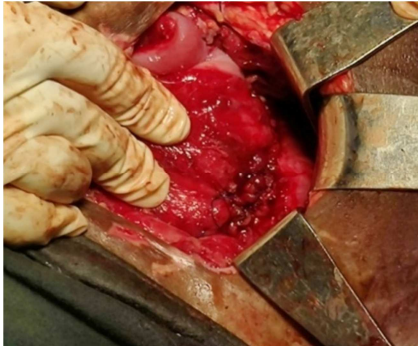


Figure 3. Uterine scar site necrosed edges debrided followed by suturing of the rent.

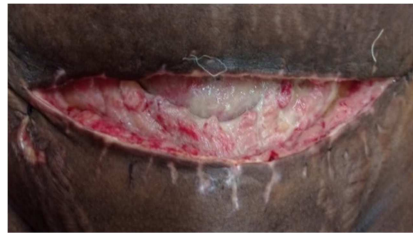

Figure 4. Full-length wound gape up to rectus muscle.

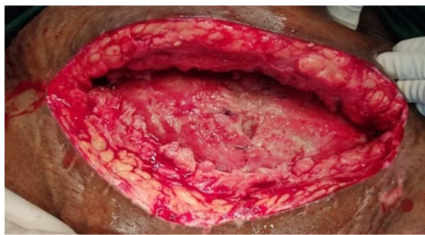

Figure 5. Debrided full-length wound before resuturing.

2.2. Case Report 2

24 years old lady with para 2 living 2 Day 12 post LSCS referred from a peripheral hospital for sepsis with acute kidney injury. She had undergone an emergency caesarean section in a peripheral hospital for a big baby and a previous caesarean section. She had a primary post-partum haemorrhage and was treated with uterotonics and blood products. The next day she was found to have low platelets (70,000) and low urine output. She was transfused with 12 random donor platelets and 1 unit of packed red blood cells. However, the patient developed anuria and underwent 7 cycles of haemodialysis subsequently. She was initially on oxygen support but was intubated on day 3 post-operatively and then referred to a tertiary care centre for further management on day 12 post-operatively.

She presented to us in a poor condition, she was febrile with 100 degrees Fahrenheit, severe pallor, mild icterus, pulse was 118 beats per minute, blood pressure 130/90mmhg, SPO₂- 100% on 70% FiO₂ on SIMV mode, and her respiratory examination showed bilateral basal crepts. Her abdomen was tense and distended, and the uterus was of 28 weeks size. The suture line showed superficial skin necrosis involving nearly half of the suture line (Figure 6). Per speculum examination showed scanty foul-smelling lochia.

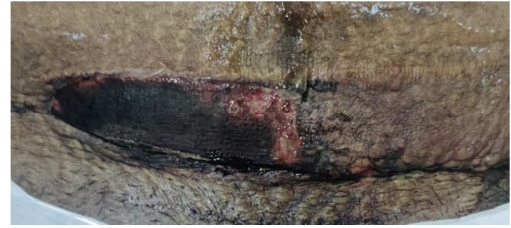

Figure 6. Suture line showing superficial skin necrosis.

Fresh blood investigations were done which showed Haemoglobin as 5.8 g/dl, leucocyte count- 24250/dl, platelet count- 45000/dl, electrolytes- sodium- 141mEq/l, potassium- 2.53mEq/l, bilirubin- 4, SGOT/SGPT- 73/20, prothrombin time- 17.6 secs and INR- 1.32, creatinine level of 3 mg/dl, urea- 121mg/dl, LDH- 3837. Ultrasonography was suggestive of a bulky uterus with intrauterine hematoma, mild ascites and bilateral kidneys with raised cortical echogenicity but maintained corticomedullary differentiation.

The patient was taken up for emergency exploratory laparotomy the same day. Intraoperatively hematoma was found in the subcutaneous tissue, intramuscularly, intraperitoneal (900gm) and hemoperitoneum off around 100 ml was drained. Uterus was found to be pale with hematoma stuck to the suture site (Figures 7 and 8). She underwent an obstetric hysterectomy with infusion of 2 pints of packed cells, 4 pints of fresh frozen plasma and 1 single donor platelet intraoperatively. Postoperatively 2 pints of packed cells and 4 pints of fresh frozen plasma were transfused additionally.

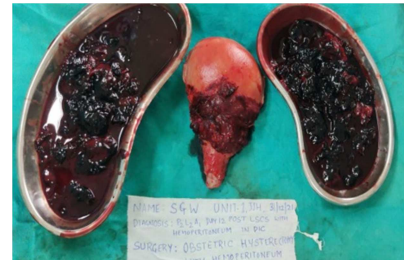

Figure 7. Uterus with cervix with uterine scar dehiscence and hemoperitoneum of 900gms of clots.

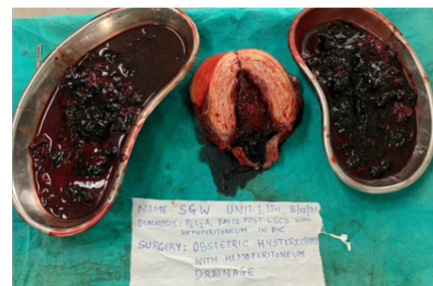

Figure 8. Cut section of the uterus with cervix showing necrosis of the suture site along with an intrauterine collection.

The patient showed improvement postoperatively and was extubated on day 4, shifted to BIPAP and then gradually weaned to oxygen support and then room air by day 20 of her exploration. However, she further required 4 cycles of haemodialysis and developed multiple febrile episodes after day

7 postoperatively with a complete wound gape. Therefore she was started on injection meropenem 1 gm twice daily and injection metronidazole 100cc thrice daily. The dressing was done daily twice and a resuturing of the abdominal wound gape after 5 days, following which the patient was discharged on day 30 of exploration after suture removal. The patient followed up after 1 month, healthy and asymptomatic.

3. Discussion

- 1) *Background:* Postpartum uterine scar dehiscence is an extremely rare but potentially lethal complication of cesarean delivery. It is defined by Rivlin et al [9] as an acute infection leading to uterine incision necrosis that may present with or without the separation of the edges. Shaamash et al cited it as 0.06% to 3.8% of cases [4].
- 2) *Aetiology of Post Caesarean uterine scar dehiscence:* Risk factors include multiparity, factors associated with poor wound healing such as old age, previous classical caesarean section, previous lower segment caesarean section, inadvertent use of uterotonics, previous surgery leading to breach in the uterine cavity like myomectomy or adenomyomectomy, Mullerian anomalies needing metroplasty, underlying medical conditions like malnutrition, diabetes, anaemia, obesity, immunosuppression, emergency surgery, infection, postpartum endomyometritis, suture technique, hematoma of uterine incision line, and incision placed too low in the lower uterine segment [5, 8, 11].

3.1. Symptomatology of Post Caesarean Uterine Scar Dehiscence

Postpartum uterine scar dehiscence can present as secondary postpartum haemorrhage, localised or generalised peritonitis, sepsis, septic shock and superficial wound infection. Uterine scar dehiscence with peritoneal infection presents with abdominal pain and tenderness, fever, tachycardia, anaemia, sepsis and in severe cases, a septic shock [1, 3, 5, 13, 16, 21, 22]. The patient can present immediately postpartum as seen in both our cases, with heavy vaginal bleeding in case 1 and febrile episodes in case 2 or can show delayed postpartum haemorrhage as late as 6-12 weeks as described by many authors [6, 10, 15, 17]. In about 17 cases reviewed from 2011 to 2022 in various studies, the most common presenting feature was fever in 8/17 cases [3, 13, 14, 18, 19, 20, 21, 22] followed by heavy vaginal bleeding 5/17 [6, 8, 10, 15, 17]; abdominal pain in 3/17 [5, 20, 22] and foul-smelling vaginal discharge in 4/17 cases [3, 5, 14, 21] (Table 1). Similarly, in our case study, we had case 1 who presented with fever and in case 2, the patient presented with heavy vaginal bleeding.

Patients presented as early as the 2nd day to as late as 6 months post-caesarean section (Table 1). However both our cases presented immediately, within 24 hours postoperatively. Patients usually had some associated risk factors that caused poor wound healing such as gestational hypertension [13, 20], gestational diabetes mellitus [15],

previous 2 LSCS [6, 20, 17, 10, 22] and PROM [5]. In our cases, case 1 had anaemia and case 1 had previous 1 LSCS with gestational hypertension.

3.2. Diagnosis of Post Caesarean Uterine Scar Dehiscence

Ultrasound images can indicate if the incision site is protruding outward, if there is a heterogeneous mass, or if the inner wound edge is irregularly shaped. According to Royo et al [2], poor wound healing should be considered if there is no blood flow signal in the mass and the edge. Pelvic angiography [17, 10, 1, 6, 10, 15], computed tomographic imaging, and magnetic resonance imaging [1, 6, 9, 14, 17] have a higher specificity in the identification of vascular abnormalities and diagnosing pelvic masses and fluid collection. MRI is more sensitive and specific in diagnosing dehiscence because it delineates the uterine serosa layer [14]. Hysteroscopy can also be a diagnostic option for abnormal uterine bleeding after a caesarean section [10]. However, a definitive diagnosis of infected uterine incisional necrosis and dehiscence is made during surgical exploration [17]. The most common radiological method of diagnosis was ultrasonography [3, 5, 6, 10, 12, 15, 20, 21] followed by CT scan [13, 22] even though MRI [14] is more sensitive, it was rarely used for diagnosis. In case 2, USG was done for the diagnosis and in case 1, USG followed by a CT scan was done for a detailed diagnosis as shown in Figure 1.

The most common organism associated was *E. coli* [6, 17, 19, 20]; however, some cases cited MRSA [22], *Proteus mirabilis* [14], *Streptococcus angiosus* [13], *Staphylococcus aureus* [21] and *Acinetobacter* [17]. In both our cases, the cultures were suggestive of no organisms.

3.3. Management of Post Caesarean Uterine Scar Dehiscence

There are no treatment guidelines, therefore based on a good level of evidence, the conservative or surgical treatment should be tailored to patients on an individual basis (e.g., clinical presentation, hemodynamic status, the severity of infection, surgical findings and patient desire to preserve fertility).

3.3.1. Medical Management

For a hemodynamically stable patient without active bleeding, conservative management with broad-spectrum antibiotics for uterine dehiscence can be considered [5]. As seen in 3 cases reported by (El-Agwany 2018), all of them had a good outcome.

3.3.2. Conservative Surgical Management

For a patient who is hemodynamically unstable or has a significant infection with signs of sepsis, exploratory laparotomy should be considered. However, it may be possible to preserve the uterus if the patient is stable and wishes to preserve her fertility; particularly if the uterus and intraabdominal organs are minimally involved by the infection and edges are regular. Abscess drainage, necrotic edges debridement, thorough peritoneal lavage along with placement of abdominal and intrauterine drain can be done [3, 13, 14, 18, 21] (figure 6). A

Conservative approach to preserve their fertility instead of resorting directly to hysterectomy can be taken in hemodynamically stable, low risk patient with low severity of infection. However, preserving the uterus does not necessarily mean preserving fertility, especially with the risk of intrauterine adhesion formation preventing conception, or cesarean scar pregnancy and uterine rupture in the subsequent pregnancy. Conservative surgical management was attempted in 5 cases [3, 13, 14, 21] which all had good outcomes except one case in which conservative surgical management was attempted but was later hysterectomy was done due to complications [18]. In our cases, conservative surgical management was opted for case 1 to conserve the fertility of the patient and as uterine reconstruction was possible and the patient was hemodynamically stable.

Dedes et al (19) described negative pressure wound treatment following surgical wound debridement with a good outcome.

3.3.3. Obstetric Hysterectomy

In cases with necrotic irregular margins with significant infection, a hysterectomy is a preferable option. Total or subtotal hysterectomy and surgical debridement with conservation of the unaffected adnexa can be done [5, 6, 10, 15, 17, 20] (figure 9). The most common treatment was an obstetric hysterectomy, done in 9/17 cases [5, 6, 10, 15, 17, 20, 22]. In our case 2, hysterectomy was done as the patient was hemodynamically unstable and definitive management to remove the foci of infection was required.

7/ 17 cases required blood and blood products, mostly in cases where the primary complaint was heavy vaginal bleeding or in which obstetric hysterectomy was conducted [5, 6, 10, 15, 17, 18, 20]. In both our cases, blood products were required as patients were anaemic and surgical management was required.

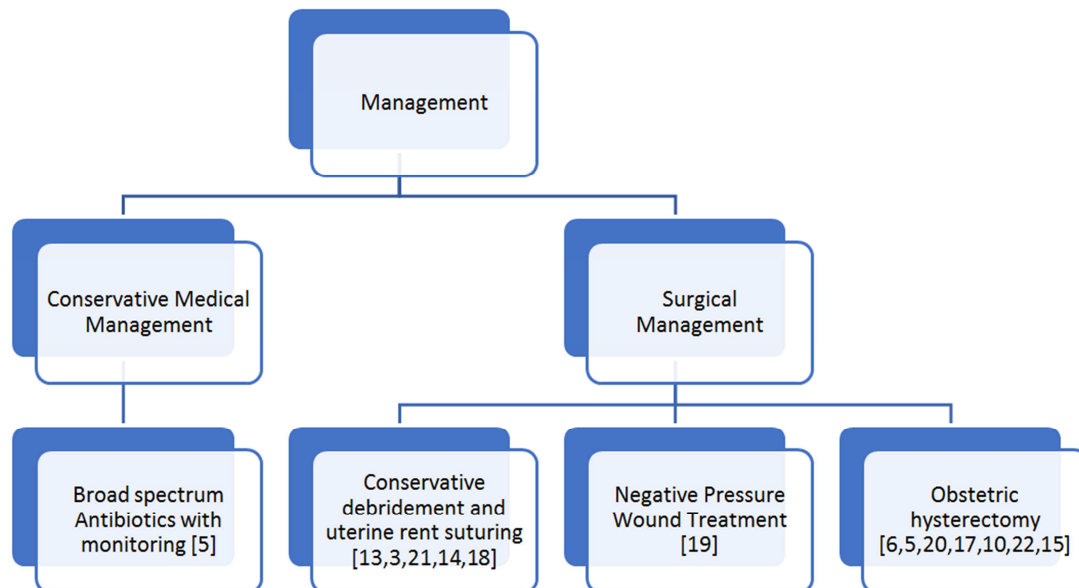


Figure 9. Summary of the management of the post caesarean uterine scar dehiscence.

4. Conclusion

Post caesarean uterine scar dehiscence requires a very high index of suspicion as a rare cause for postpartum peritonitis and sepsis and delayed postpartum haemorrhage. Diagnostic tools like ultrasonography (transvaginal/abdominal), CT scan, MRI or pelvic angiography can be used to adjunct our clinical diagnosis. Severe abdominal wound infection after caesarean section may be associated with uterine wound dehiscence, which poses a grave risk to the mother with severe morbidity and possible mortality needing prompt patient tailored treatment.

Abbreviations

LSCS: Lower Segment Caesarean Section
 POD: Pouch of Douglas
 CT: Computerized Tomography

SIMV: Synchronized intermittent mandatory ventilation
 BIPAP: Bi-level positive airway pressure
 MRI: Magnetic Resonance Imaging
 USG: Ultrasonography
 MRSA: Methicilin resistant staphylococcus aureus
 PRC: Packed RBC Cells
 FFP: Fresh Frozen Plasma

Conflict of Interest

The authors declare that they have no competing interests.

Contributions

G Bahuguna – Project development, manuscript writing
 N Shaikh – Manuscript writing
 A Anand - Manuscript editing
 P Swain - Data collection
 R Thatikonda - Data collection

References

- [1] Wagner, M. S., & Bédard, M. J. (2006). Postpartum Uterine Wound Dehiscence: A Case Report. *Journal of Obstetrics and Gynaecology Canada*, 28 (8), 713–715. [https://doi.org/10.1016/S1701-2163\(16\)32236-8](https://doi.org/10.1016/S1701-2163(16)32236-8).
- [2] Royo, P., García Manero, M., Olartecoechea, B., & Alcázar, J. L. (2009). Two-dimensional power Doppler-three-dimensional ultrasound imaging of a cesarean section dehiscence with utero-peritoneal fistula: A case report. *Journal of Medical Case Reports*, 3. <https://doi.org/10.1186/1752-1947-3-42>.
- [3] Alwani M, Mishra S, Thakur R. Generalized peritonitis with uterine incision necrosis with dehiscence following cesarean section presenting as genitourinary fistula: A unique complication. *J Med* 2014; 3: 762-6.
- [4] Shaamash, A. H., Ahmed, A. G. M., Abdel Latef, M. M., & Abdullah, S. A. (2007). Routine postpartum ultrasonography in the prediction of puerperal uterine complications. *International Journal of Gynecology & Obstetrics*, 98 (2), 93–99. <https://doi.org/10.1016/J.IJGO.2007.03.042>.
- [5] El-Agwany, A. S. (2018). Conservative management of infected postpartum uterine dehiscence after cesarean section. *Journal of Medical Ultrasound*, 26 (1), 59–61. https://doi.org/10.4103/JMU.JMU_5_18.
- [6] Sengupta Dhar, R., & Misra, R. (2012). Postpartum Uterine Wound Dehiscence Leading to Secondary PPH: Unusual Sequelae. *Case Reports in Obstetrics and Gynecology*, 2012, 1–3. <https://doi.org/10.1155/2012/154685>.
- [7] Usta IM, Hamdi MA, Musa AA, Nassar AH. Pregnancy outcome in patients with previous uterine rupture. *Acta Obstet Gynecol Scand* 2007; 86: 172-6.
- [8] Ida A, Kubota Y, Nosaka M, Ito K, Kato H, Tsuji Y, et al. Successful management of a caesarean scar defect with dehiscence of the uterine incision by using wound lavage. *Case Rep Obstet Gynecol* 2014; 2014: 421014.
- [9] Rivlin ME, Carroll CS, Sr., Morrison JC. Infectious necrosis with dehiscence of the uterine repair complicating cesarean delivery: a review. *Obstet Gynecol Surv.* 2004; 59 (12): 833-837.
- [10] Zhang Y, Ma NY, Pang XA. Uterine incision dehiscence 3 mo after cesarean section causing massive bleeding: A case report. *World J Clin Cases* 2020; 8 (11): 2392-2398.
- [11] di Spiezio Sardo, A., Saccone, G., McCurdy, R., Bujold, E., Bifulco, G., & Berghella, V. (2017). Risk of Cesarean scar defect following single- vs double-layer uterine closure: systematic review and meta-analysis of randomized controlled trials. *Ultrasound in Obstetrics and Gynecology*, 50 (5), 578–583. <https://doi.org/10.1002/uog.17401>.
- [12] El Agwany, A. S. (2020). Gynecological and postpartum ultrasonography of cesarean uterine scar defects: a pictorial essay. *Journal of Ultrasound*, 23 (4), 613–619. <https://doi.org/10.1007/S40477-019-00403-3>.
- [13] Treszezamsky, A. D., Feldman, D., & Sarabanchong, V. O. (2011). Concurrent postpartum uterine and abdominal wall dehiscence and Streptococcus anginosus infection. *Obstetrics and Gynecology*, 118 (2 PART 2), 449–451. <https://doi.org/10.1097/AOG.0b013e31821619e9>.
- [14] Badr, D. A., al Hassan, J. M., & Ramadan, M. K. (2017). Conservative Surgical Management of Uterine Incisional Necrosis and Dehiscence After Primary Cesarean Delivery Due to Proteus mirabilis Infection: A Case Report and a Review of Literature. *Journal of Clinical Gynecology and Obstetrics*, 6 (3–4), 65–70. <https://doi.org/10.14740/jcgo451w>.
- [15] Thakur, G., Karmakar, P., Gupta, P., & Saha, S. C. (2021). Uterine Scar Dehiscence: A Rare Cause of Life-Threatening Delayed Secondary Postpartum Hemorrhage—A Case Report and Literature Review. *Journal of Obstetrics and Gynecology of India*, 71 (6), 629–632. <https://doi.org/10.1007/s13224-021-01493-y>.
- [16] El-Agwany, Ahmed Samy. "Postpartum uterine caesarean incision necrosis and pelvis abscess managed by hysterectomy: a complication of puerperal endomyometritis." *Res J Med Sci* 8.2 (2014): 53-55.
- [17] Aggarwal, P., Ali, Z., & Sharma, A. (2019). Uterine Scar Dehiscence Rare Cause of Secondary Postpartum Hemorrhage-A Case Report. In *International Journal of Obstetrics and Gynaecology Research (IJOG)* (Vol. 6, Issue 3). <http://www.ijogr.com/http://www.ijogr.com/>
- [18] Nigam A, Gupta N, Elahi AA, Jairajpuri ZS, Batra S. Delayed Uterine Necrosis: Rare Cause of Nonhealing Wound. *J Clin Diagn Res.* 2016; 10 (12): QD01-QD02.
- [19] Dedes I, Krahenmann F, Ghisu GP, Birindelli E, Zimmermann R, Ochsenbein N. Negative pressure wound treatment for uterine incision necrosis following a cesarean section. *Case Rep Perinatal Med.* 2016; 5 (2): 105-108.
- [20] Chaudhry S, Hussain R. Postpartum infection can be a disaster. *Pak J Med Dent* 2014; 3 (4): 70-73.
- [21] Bharatam KK, Sivaraja PK, Abineshwar NJ, Thiagarajan V, Thiagarajan DA, Bodduluri S, Sriraman KB, Vasantha Ragavan A, Priya S. The tip of the iceberg: Post caesarean wound dehiscence presenting as abdominal wound sepsis. *Int J Surg Case Rep.* 2015; 9: 69-71. doi: 10.1016/j.ijscr.2015.02.013. Epub 2015 Feb 11. PMID: 25728672; PMCID: PMC4392185.
- [22] More, Shweta & Chavan, Niranjana & Chagede, Pradnya & Charaya, Menakshi. (2020). Postpartum uterine scar dehiscence with abdominal sepsis: Rare sequelae. *Indian Journal of Obstetrics and Gynecology Research.* 7. 611-613. 10.18231/j.ijogr.2020.129.